

IRBMS

Institut Régional de Biologie et de Médecine du Sport

NORD-PAS-DE-CALAIS – WWW.IRBMS.COM

Titre : « IMAGES RADIOLOGIQUES DE LA MALADIE D'OSGOOD-SCHLATTER »

Auteur(s) : Dr Patrick Bacquaert.

Catégorie : Sport chez l'Enfant - Diaporama, 20 vues.

Date de présentation :

Lieu :

Mis à disponibilité sur le site : www.irbms.com le 22.11.05

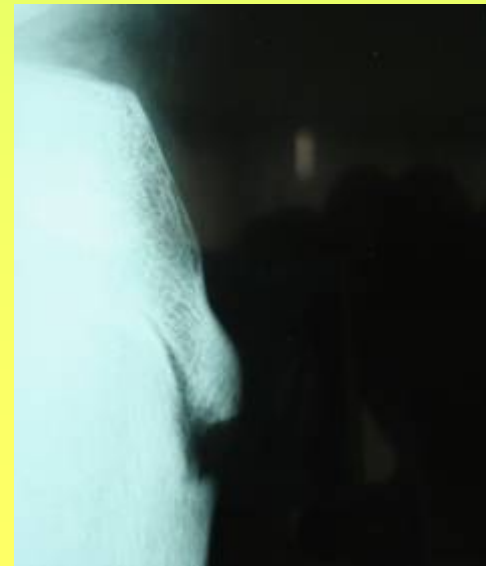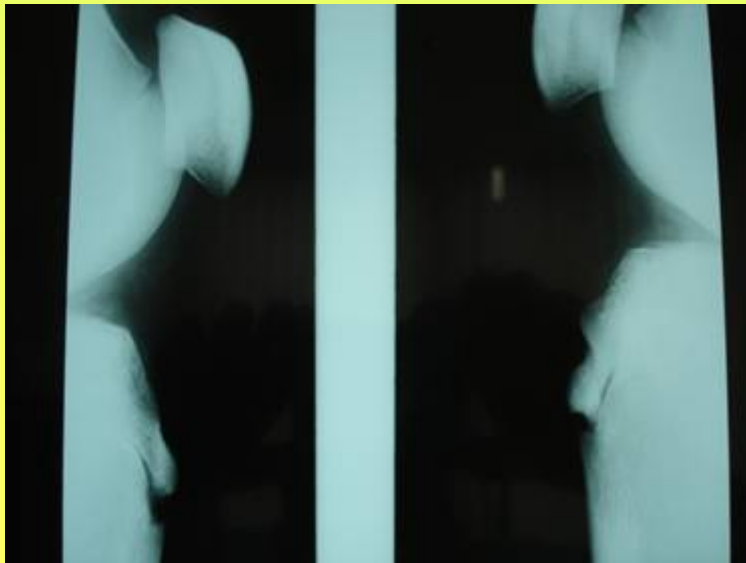
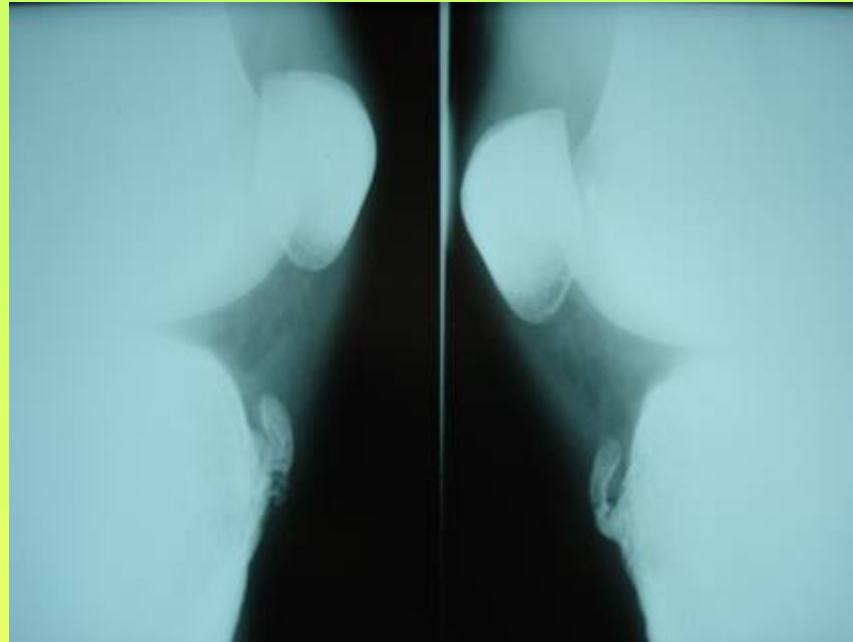
Rappel : Ce diaporama, propriété exclusive de son/ses concepteur(s), ne peut être reproduit, ni diffusé en public, même partiellement sans autorisation expresse écrite. Pour ce faire veuillez nous envoyer votre demande à l'adresse suivante : contact@medecinedusport.fr

Note : Utilisez la Barre d'espace de votre clavier pour passer d'une diapositive à l'autre.

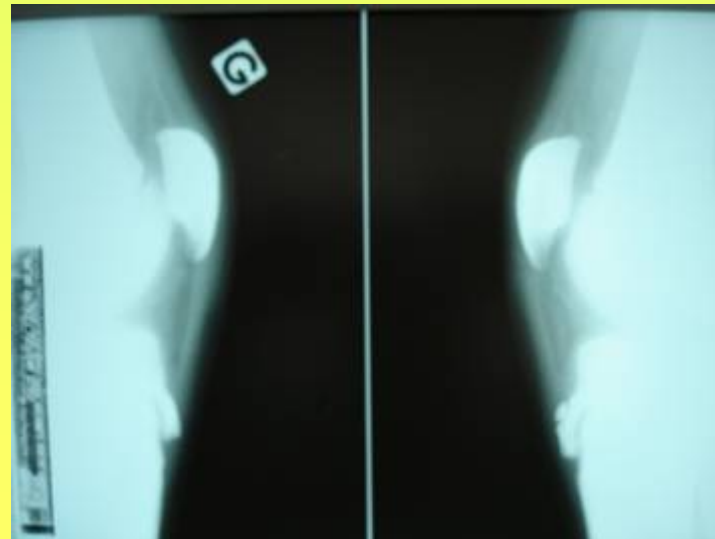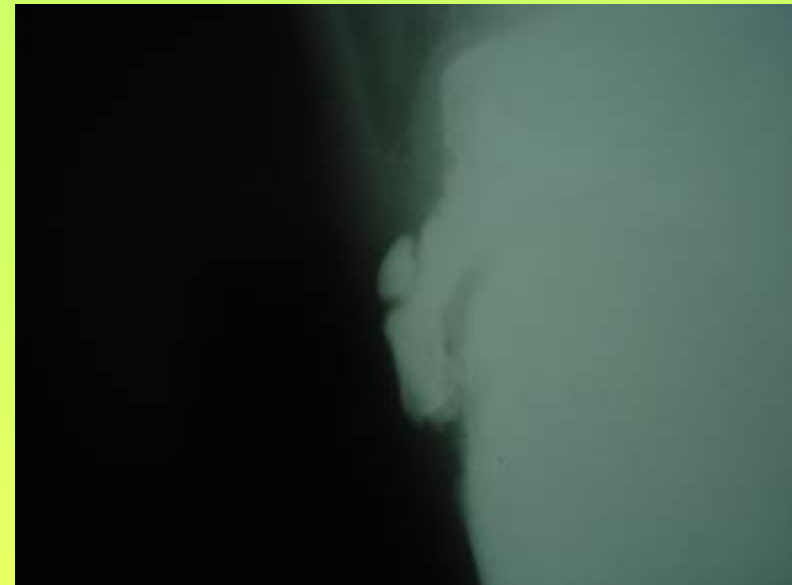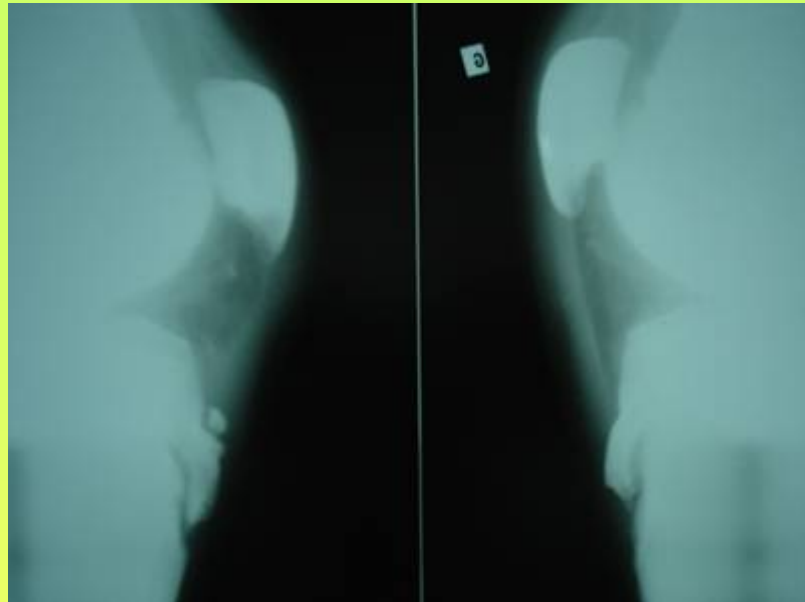
IMAGES RADIOLOGIQUES DE LA MALADIE D'OSGOOD-SCHLATTER

Docteur Patrick BACQUAERT
Médecin-Chef de l'IRBMS
www.medecinedusport.fr

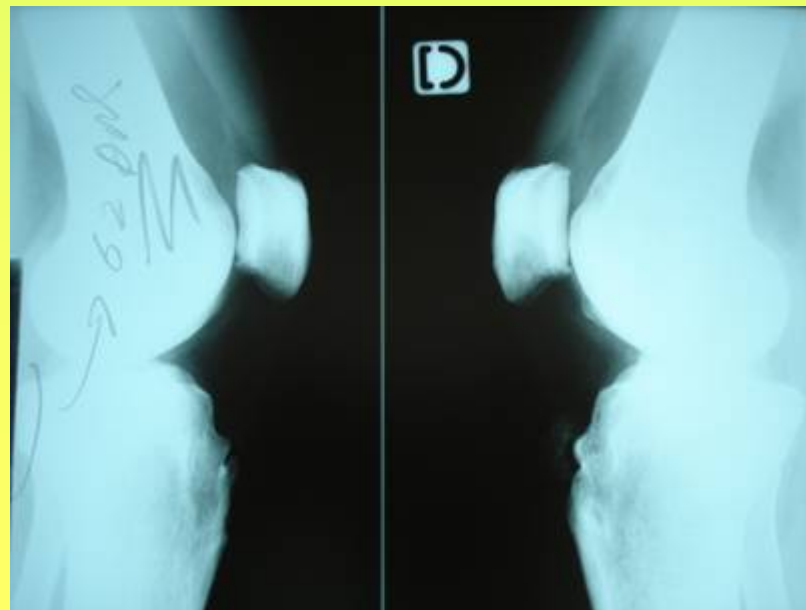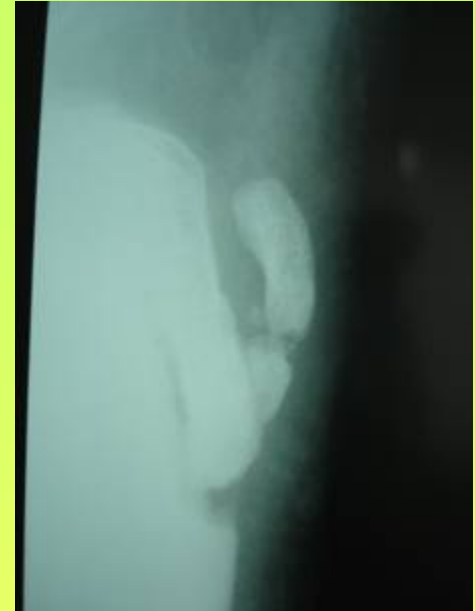
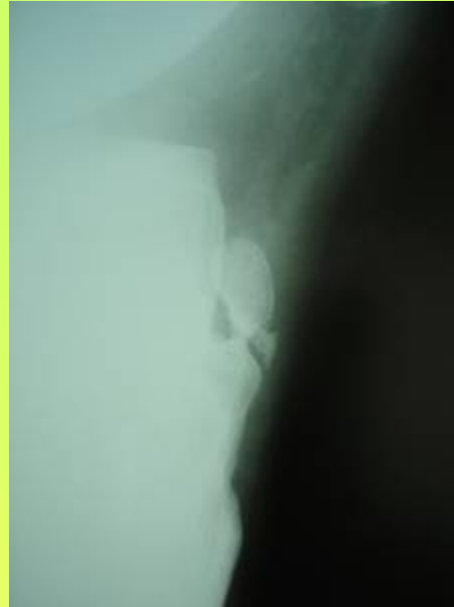
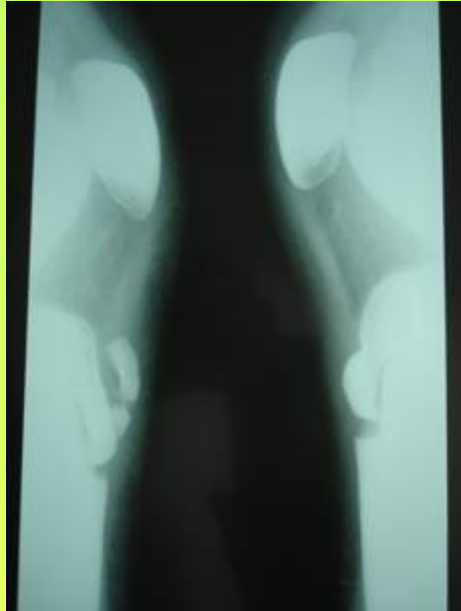OSGOOD SCHLATTER



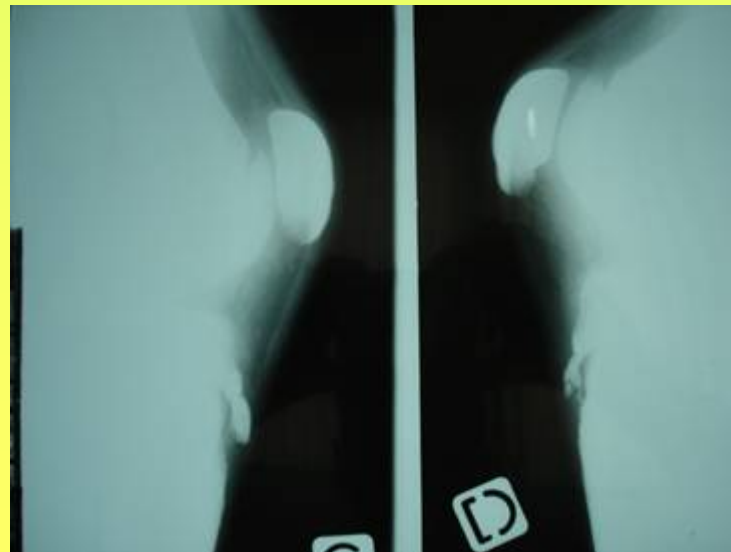
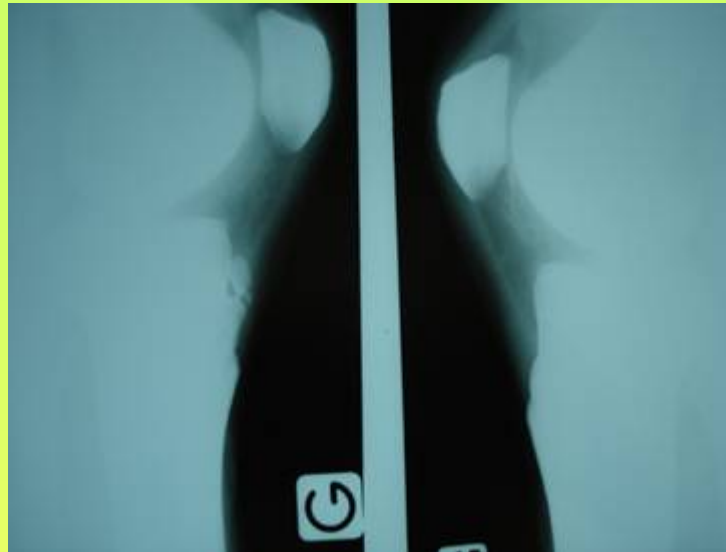
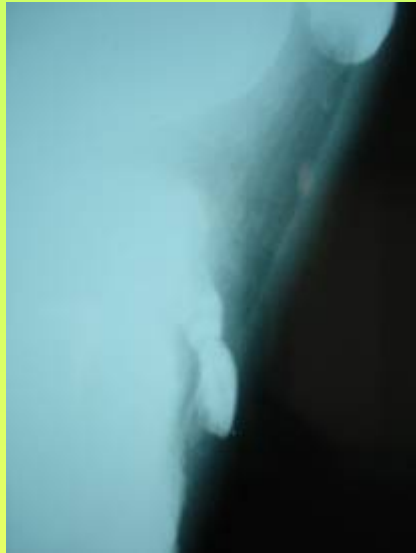
OSGOOD SCHLATTER



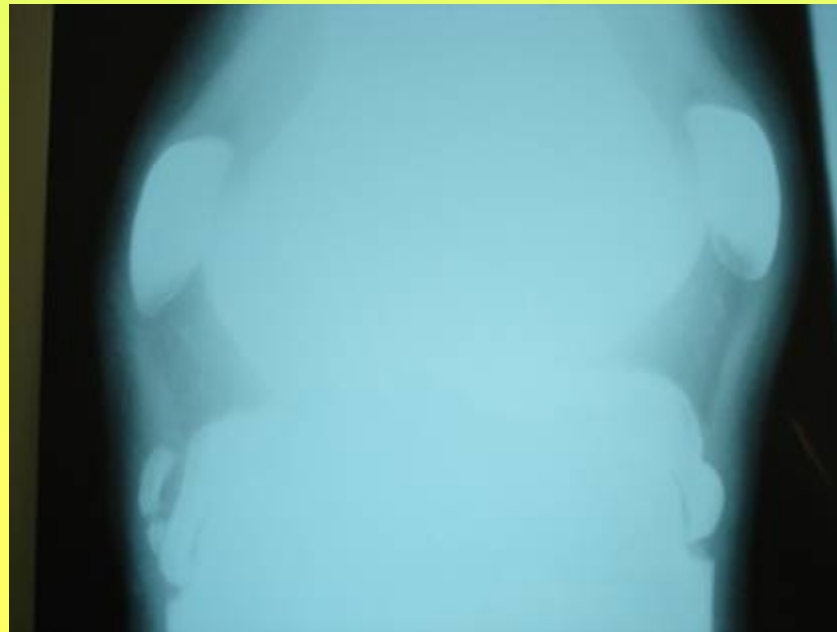OSGOOD SCHLATTER



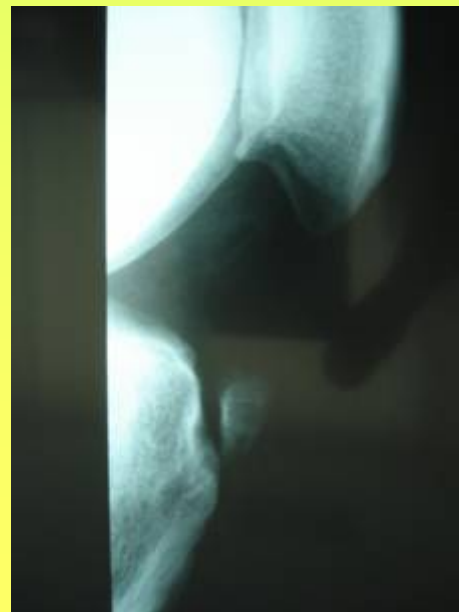
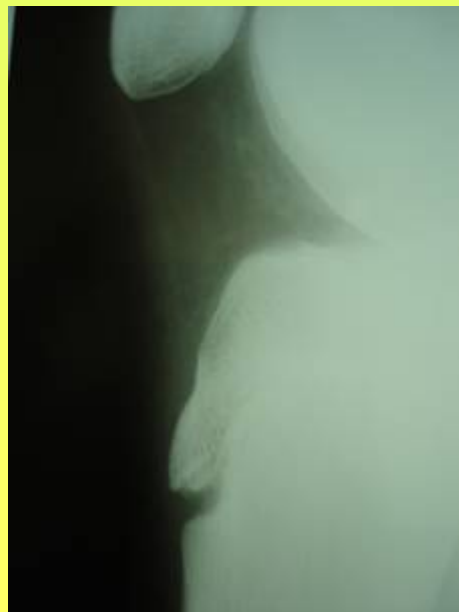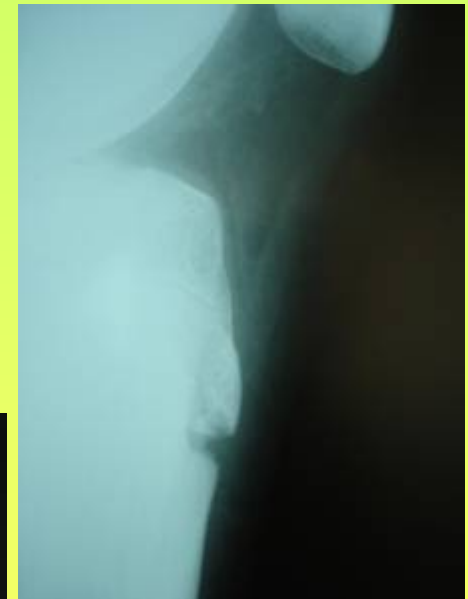
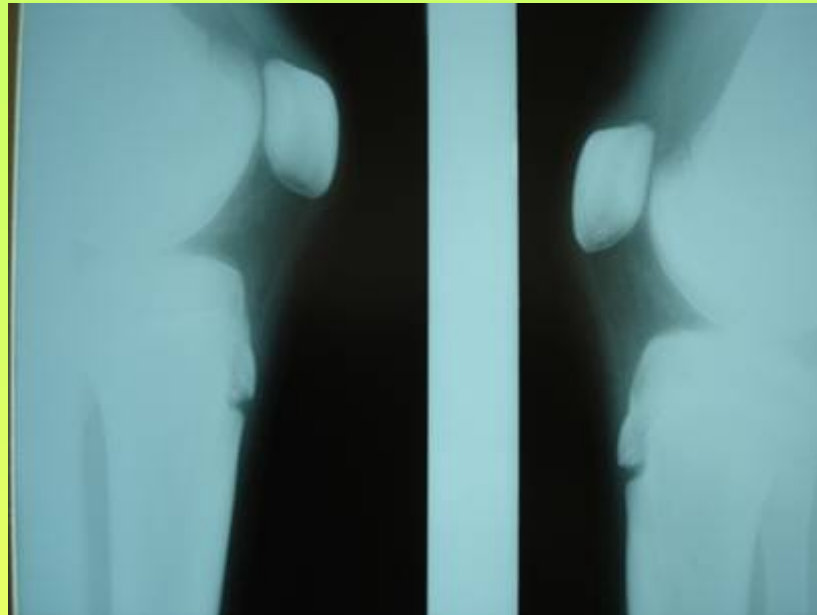
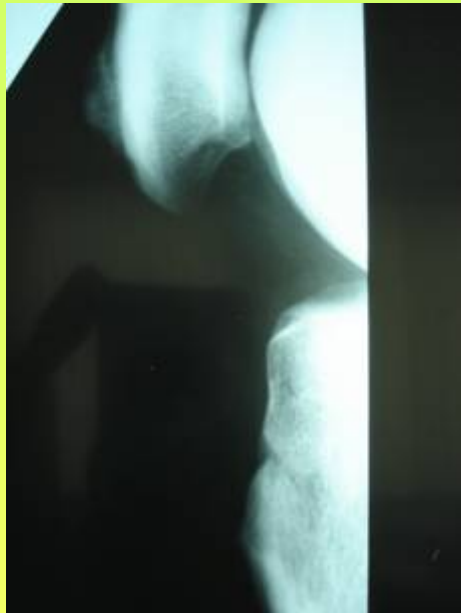
OSGOOD SCHLATTER



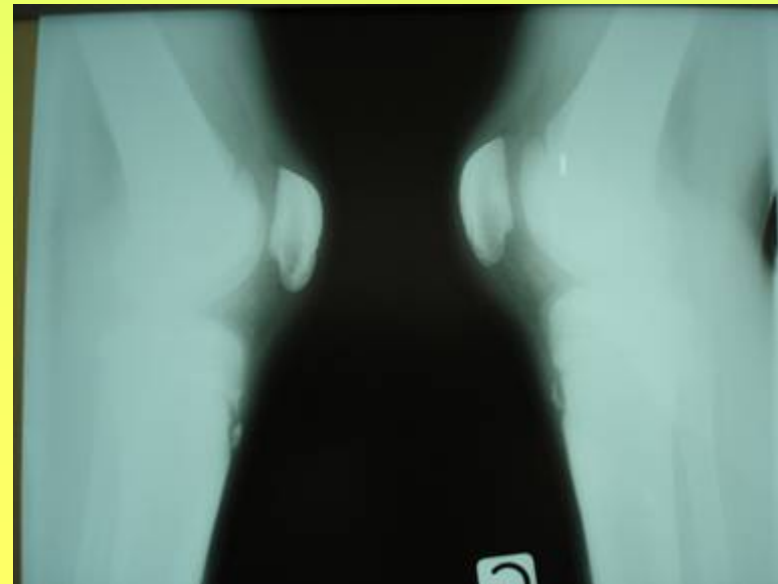
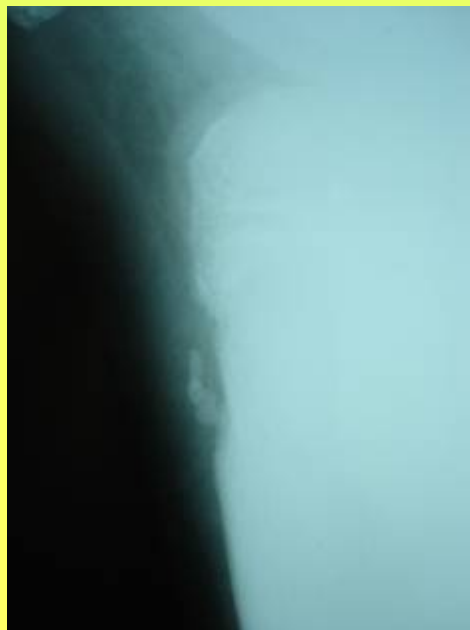
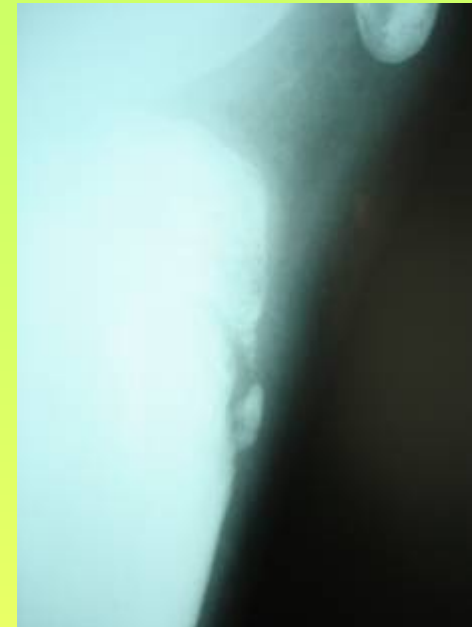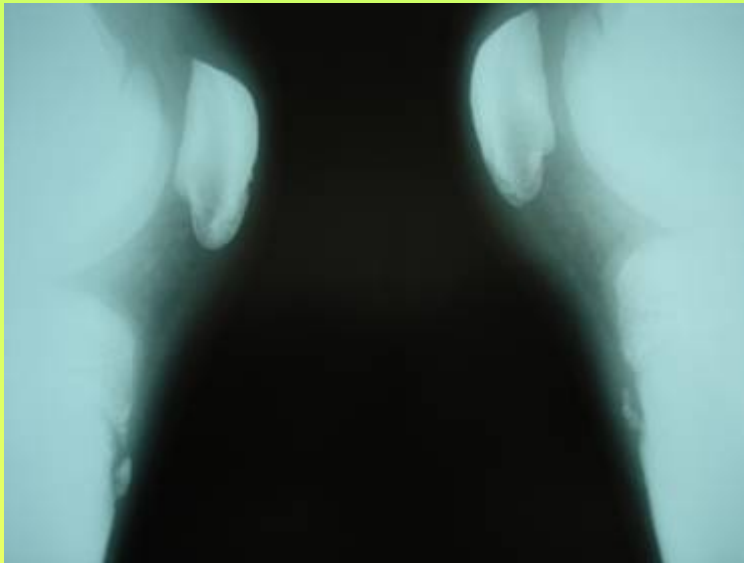
OSGOOD SCHLATTER



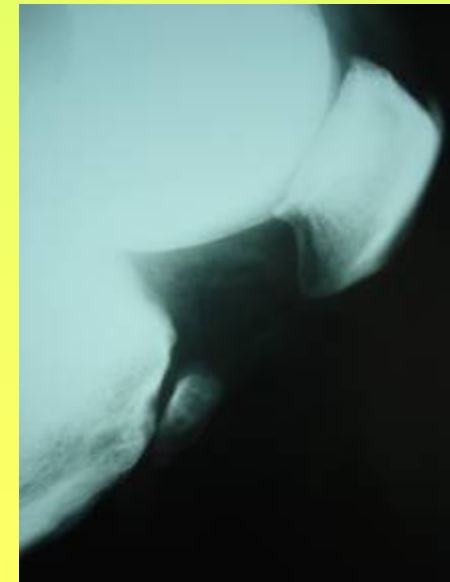
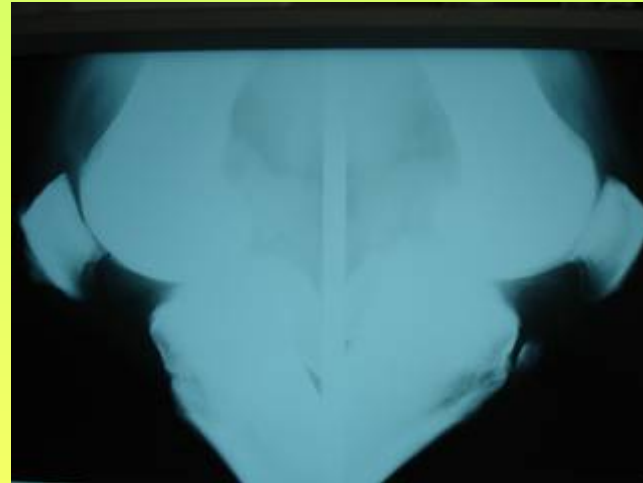
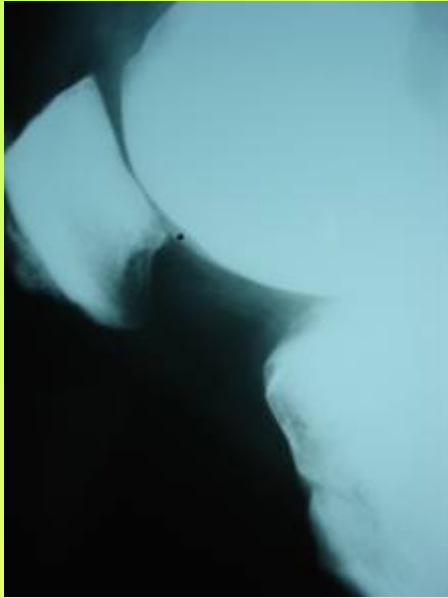
OSGOOD SCHLATTER



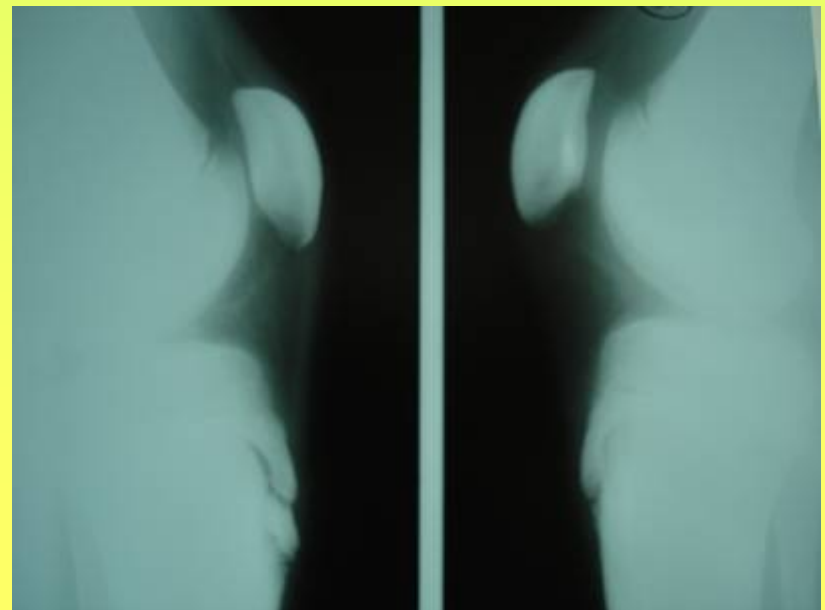
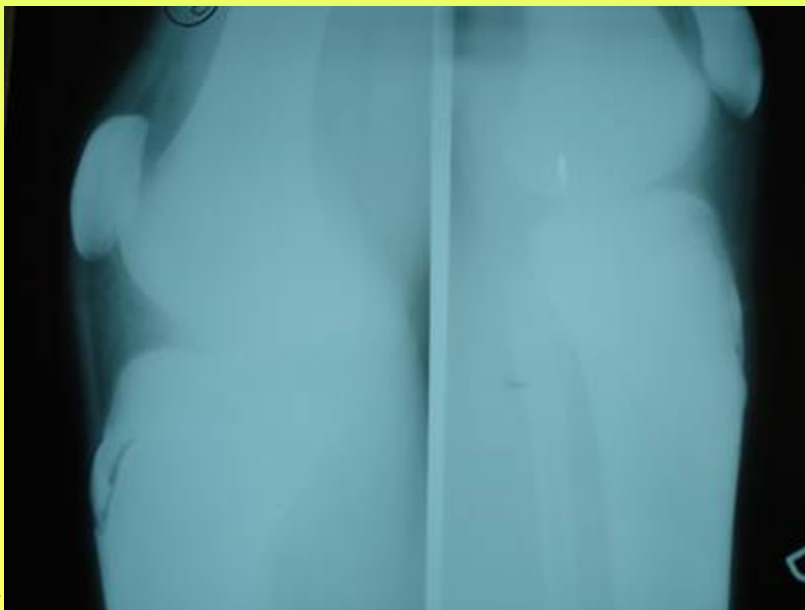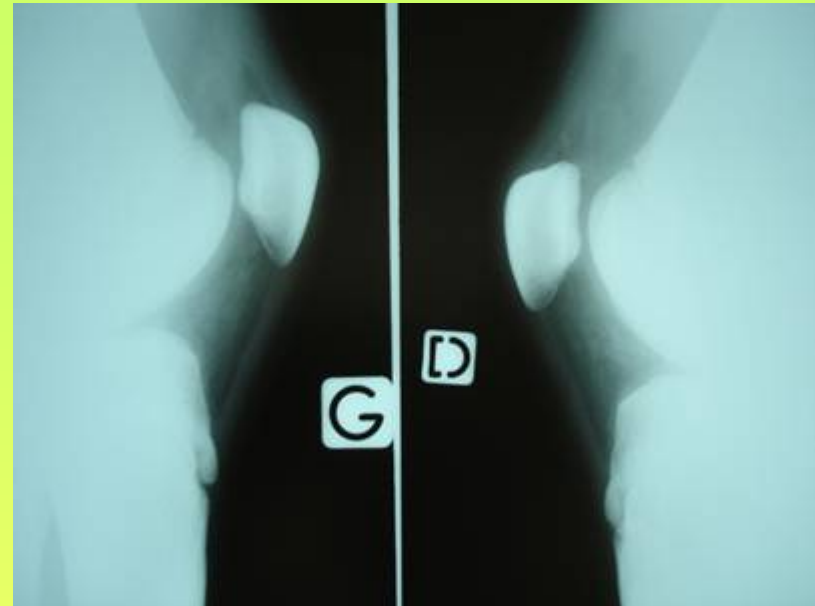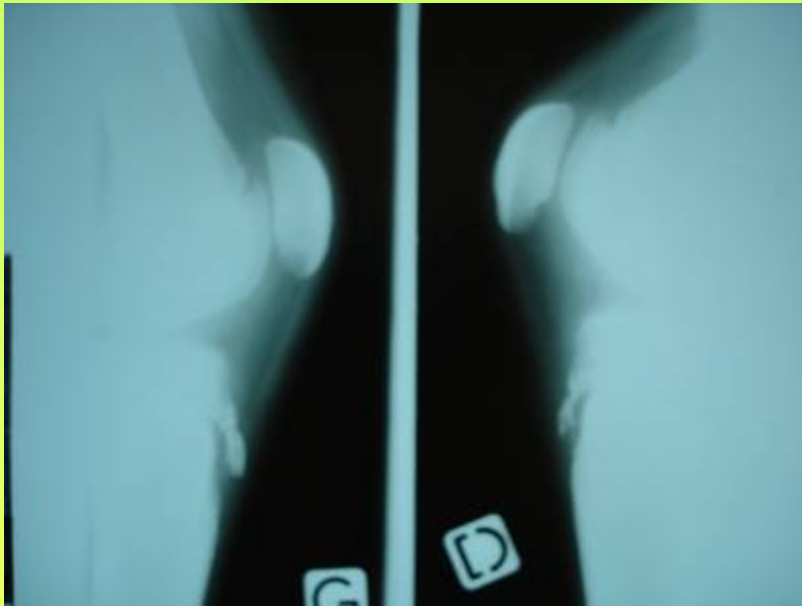
OSGOOD SCHLATTER



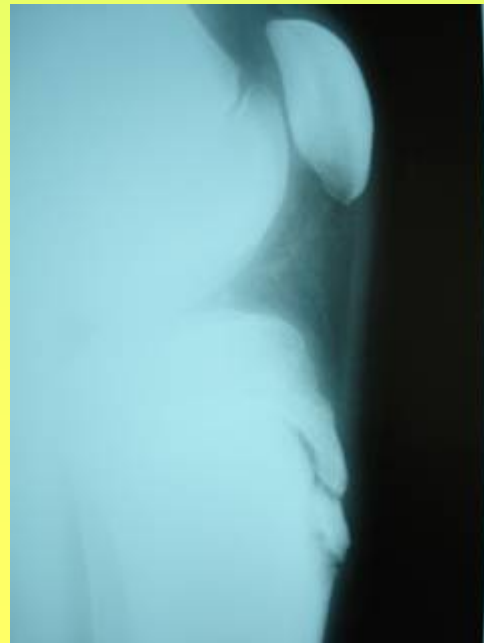
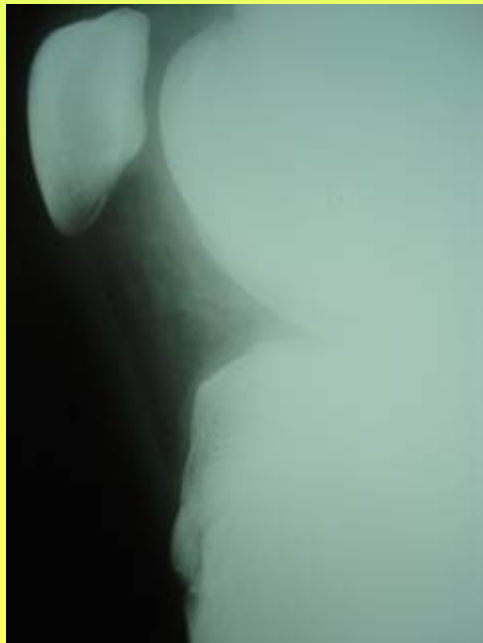
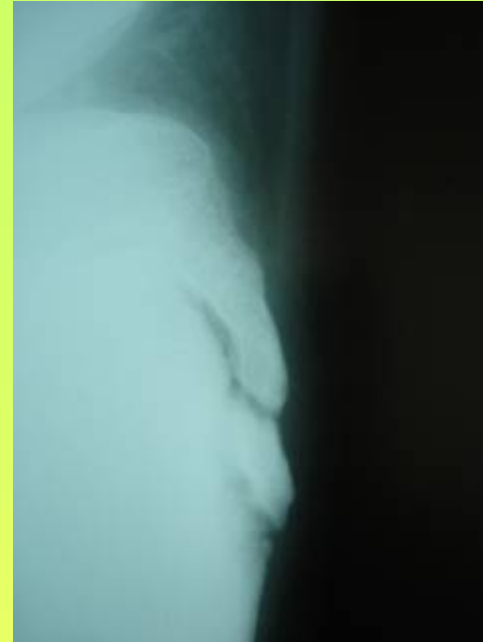
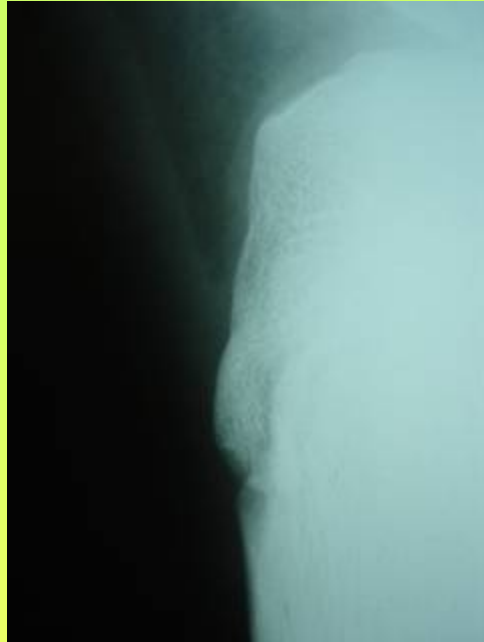
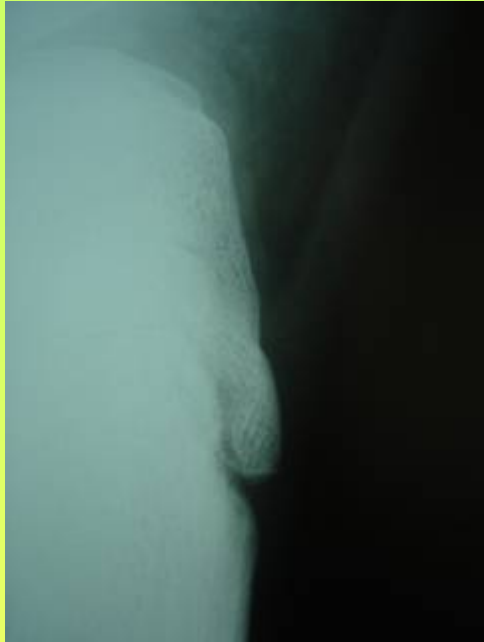
OSGOOD SCHLATTER



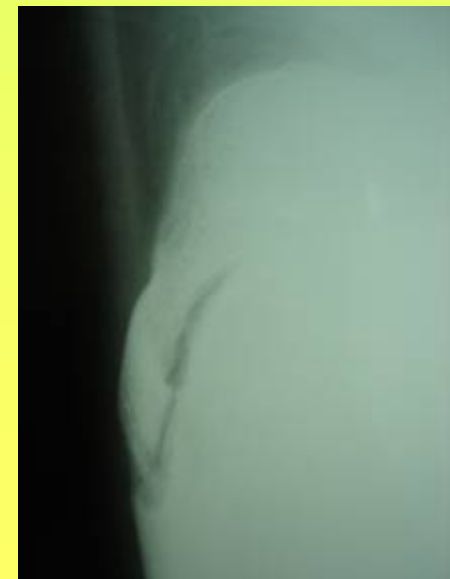
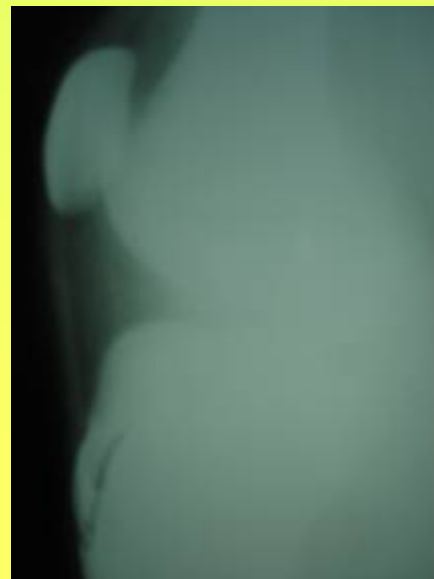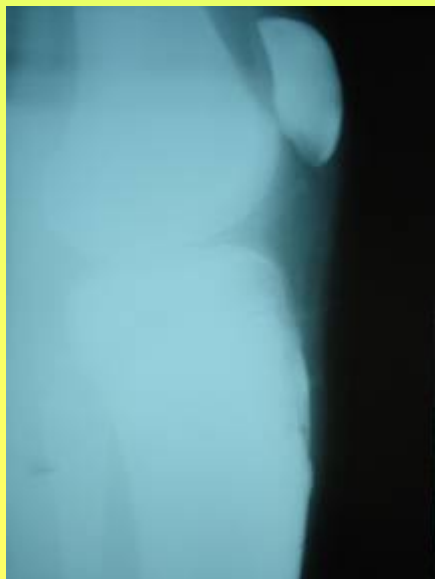
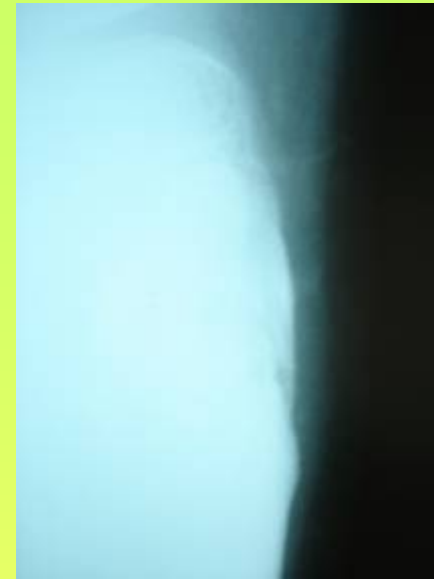
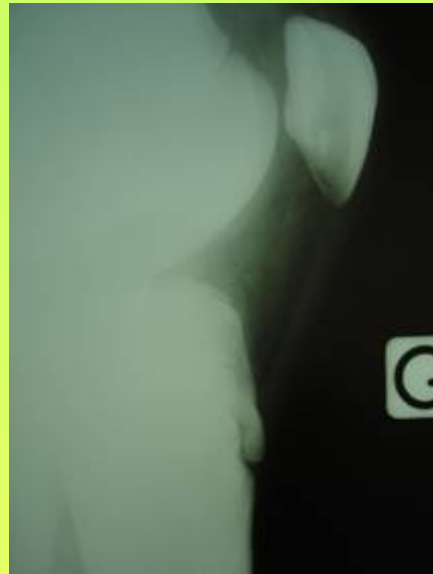OSGOOD SCHLATTER



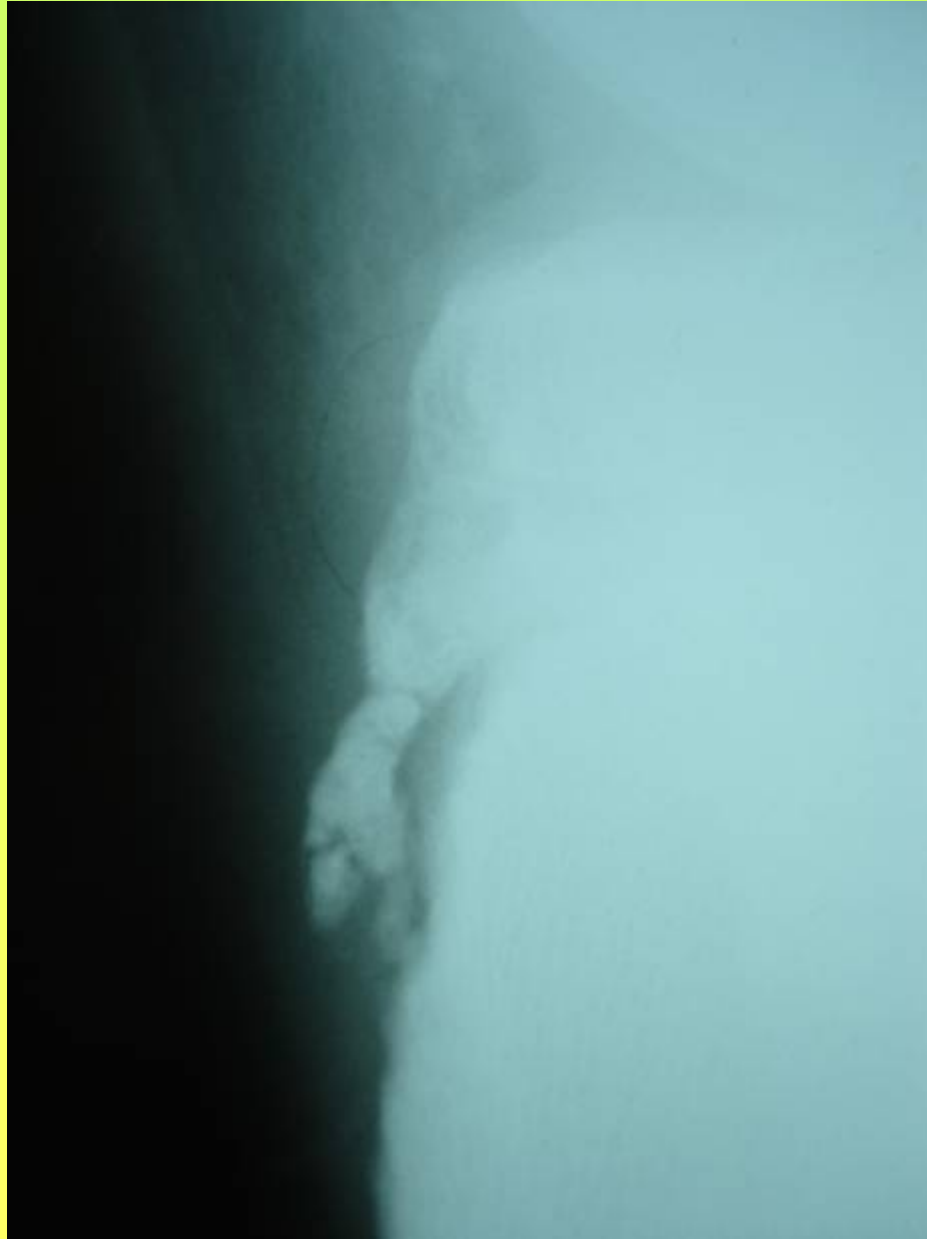
OSGOOD SCHLATTER



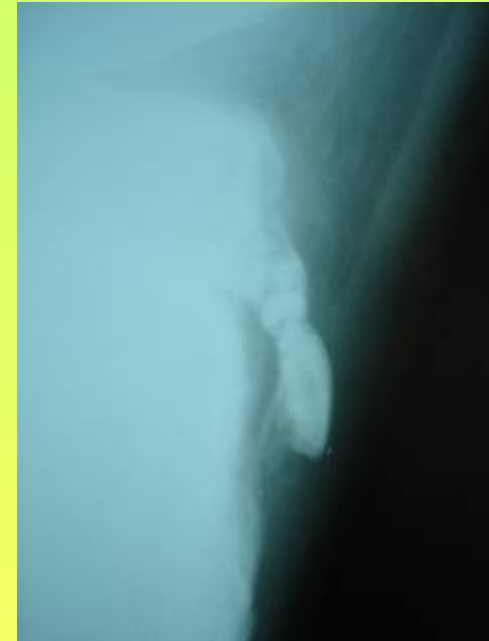
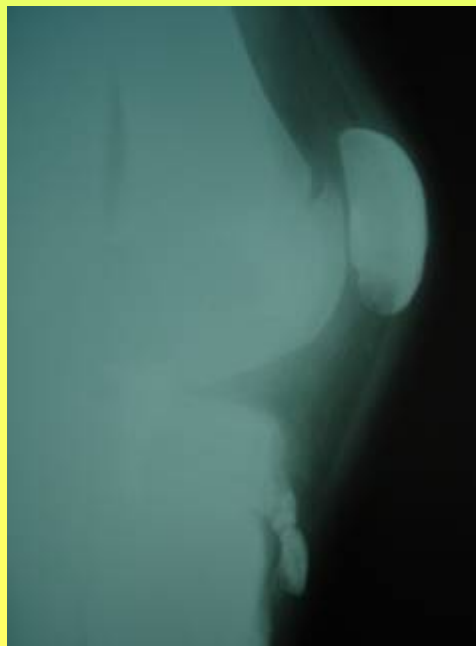
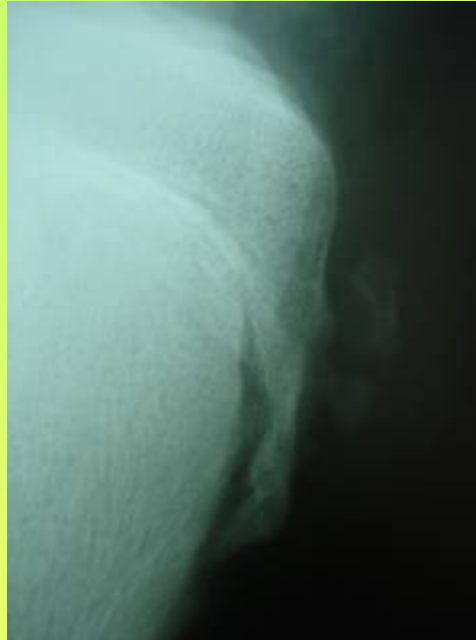
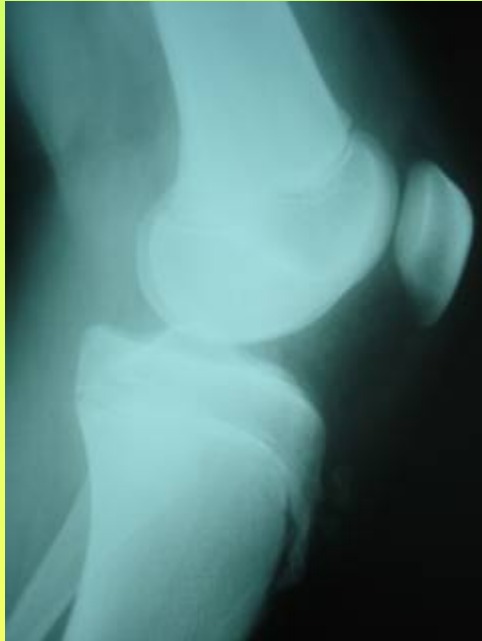
OSGOOD SCHLATTER



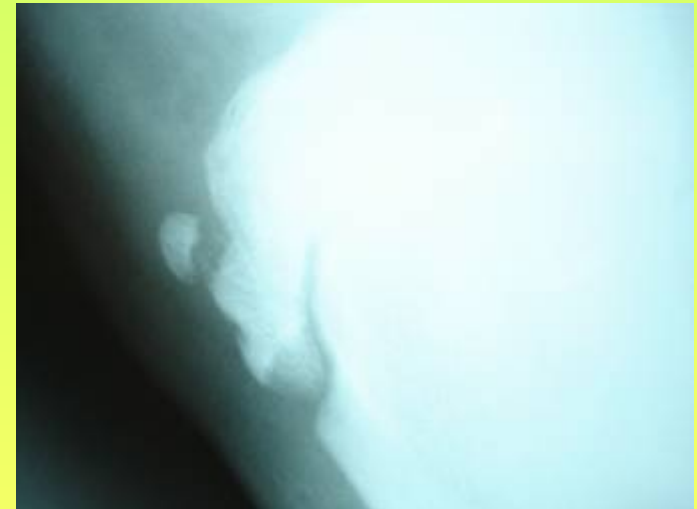
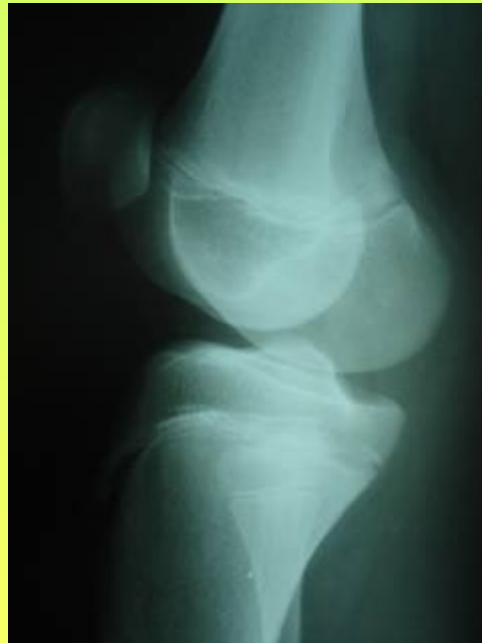
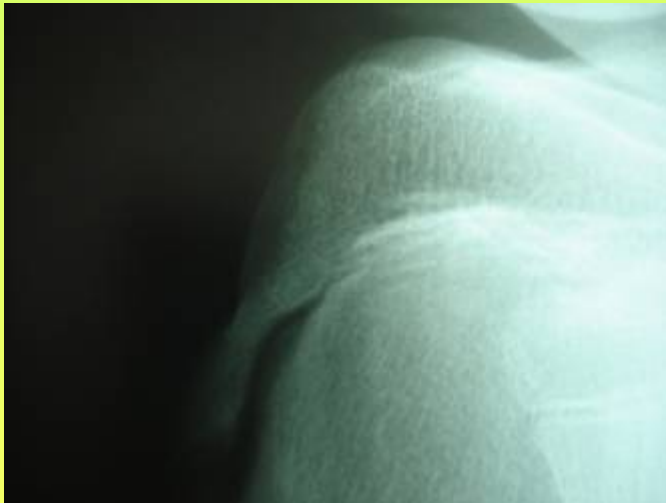
OSGOOD SCHLATTER



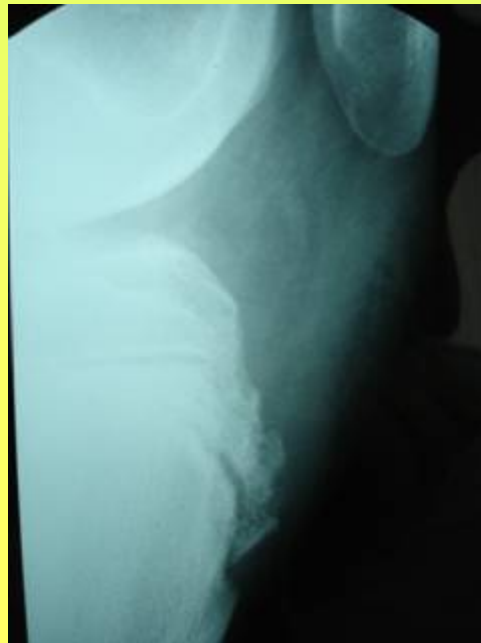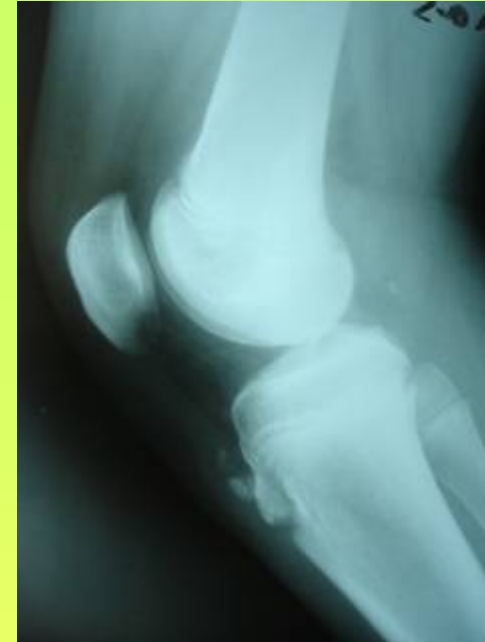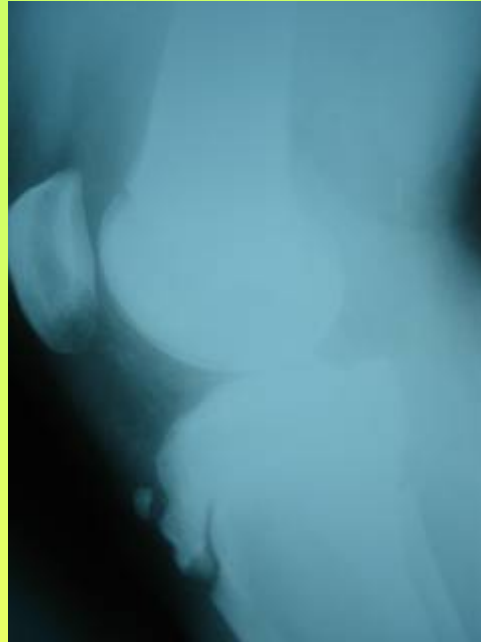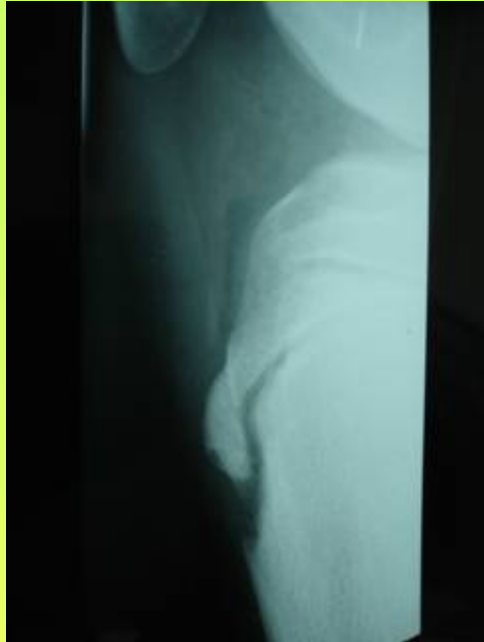OSGOOD SCHLATTER



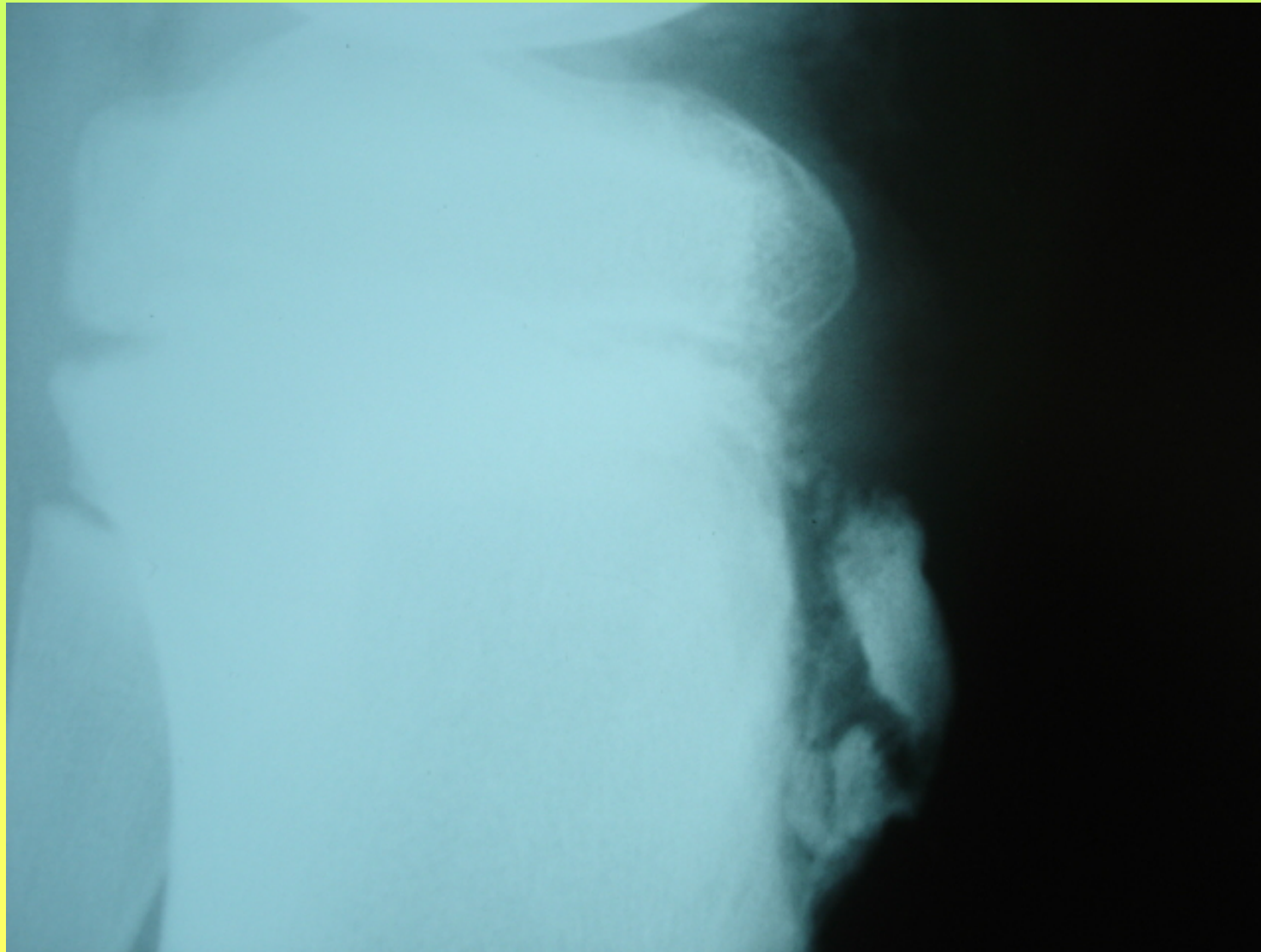OSGOOD SCHLATTER



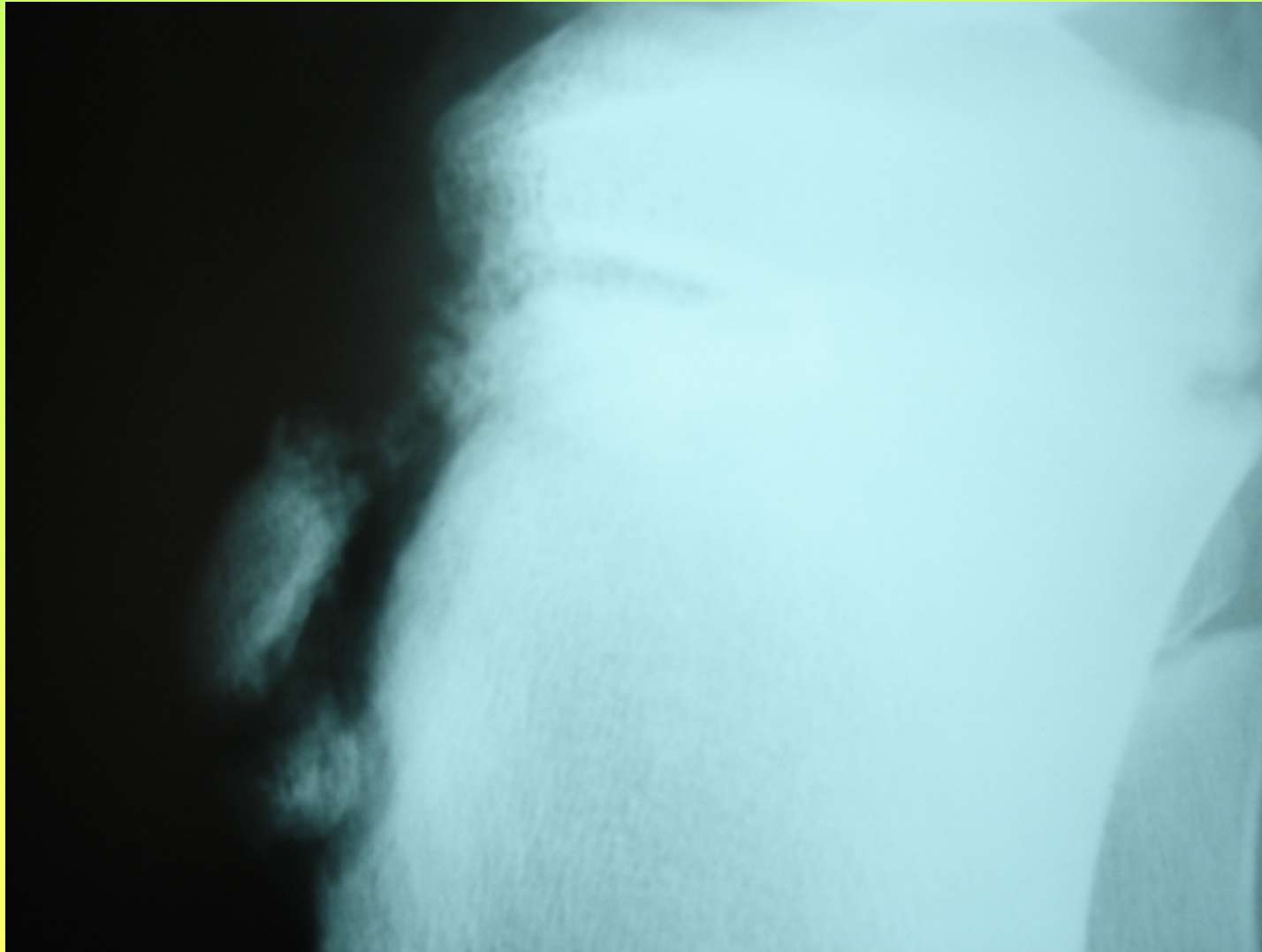
OSGOOD SCHLATTER



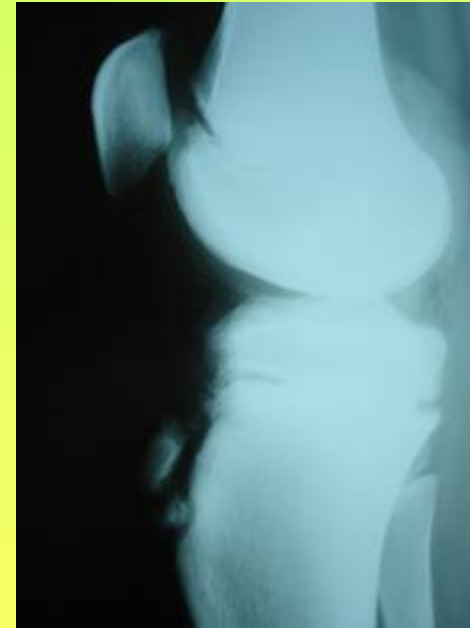
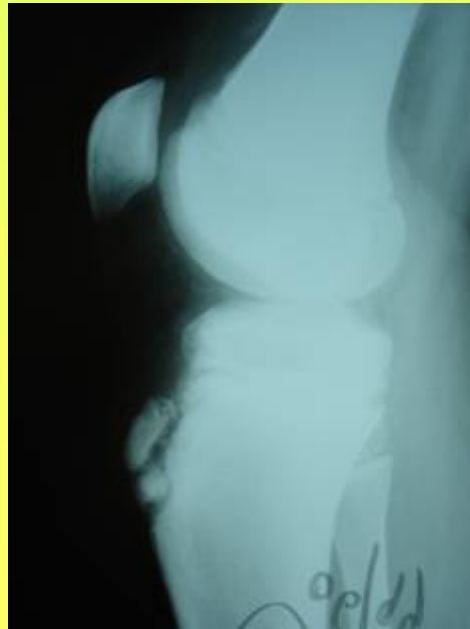
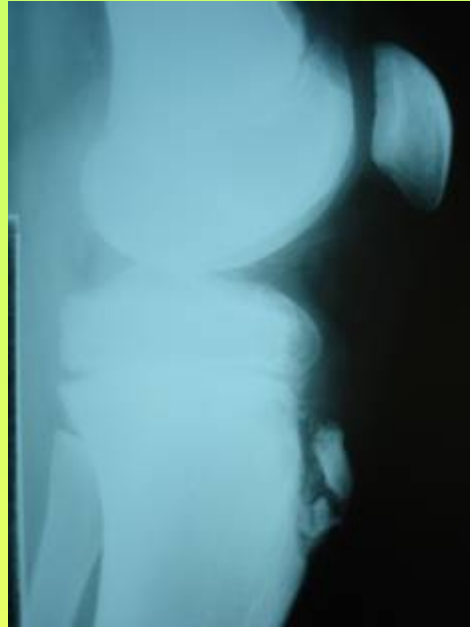
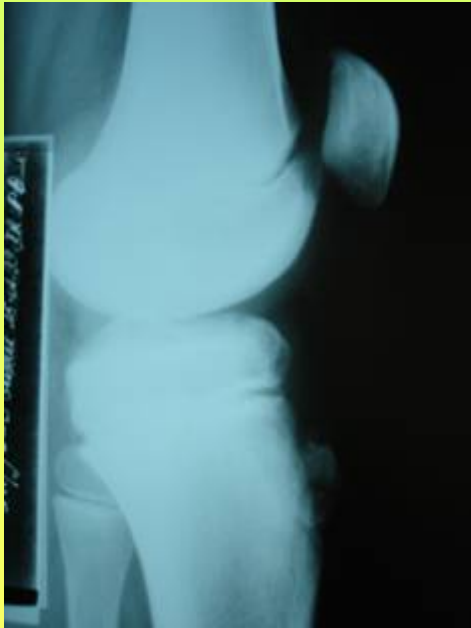
OSGOOD SCHLATTER



OSGOOD SCHLATTER



OSGOOD SCHLATTER



CONCLUSION

Le bilan radiologique suffit à lui-même pour permettre le diagnostic et le suivi de la maladie d'Osgood chez l'enfant.